

# Paquimeningitis hipertrófica idiopática en un anciano

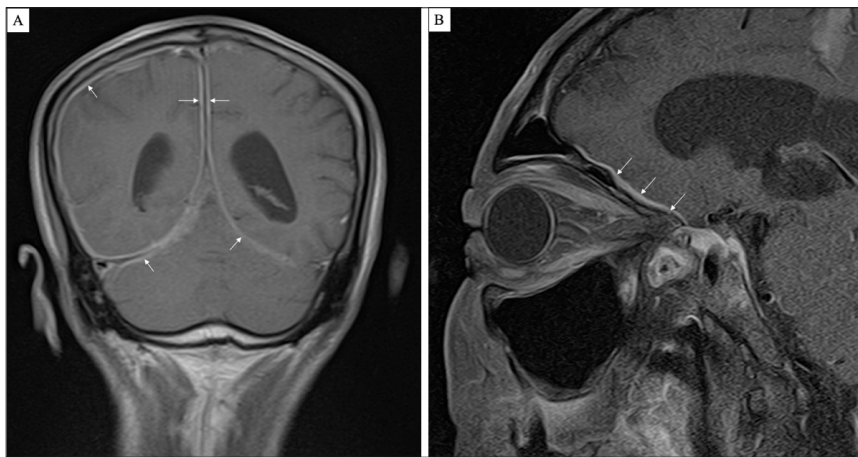
## Signo de Eiffel de noche

# Idiopathic hypertrophic pachymeningitis in an elderly man

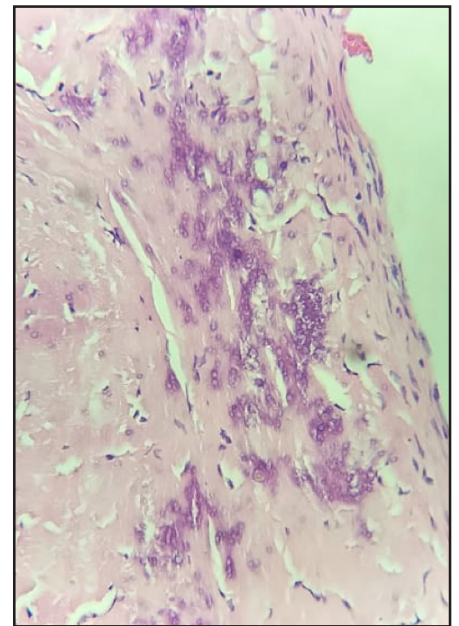
## Eiffel-by-night sign

MAURICIO ANDRÉS URIBE-VALENCIA, JANETH JURADO-DELGADO • CALI (COLOMBIA)

DOI: <https://doi.org/10.36104/amc.2021.1871>



**Figure 1.** A: Brain NRM with gadolinium, coronal view. Diffuse meningeal thickening, mainly on the right, with significant enhancement on diffuse gadolinium application, compatible with pachymeningitis. B: Orbital NRM with gadolinium. Diffuse pachymeningitis changes which reach the left and right orbital fissures.



**Figure 2.** Meningeal biopsy (H&E 40X). Fibroconnective tissue can be seen, with fibroblast proliferation, increased collagen, calcifications and mononuclear inflammatory infiltrate throughout its thickness, compatible with pachymeninge.

A 71-year-old hypertensive male who was an active smoker (IPA 51) was admitted to the emergency room due to progressively decreasing bilateral eyesight to the point of bilateral amaurosis, without ocular pain. This was associated with a chronic bilateral pulsatile frontal headache. A brain NMR showed diffuse meningeal thickening related to pachymeningitis. A meningeal biopsy showed pachymeninge. Neoplastic, infectious and autoimmune causes were ruled out; therefore, it was considered to be idiopathic hypertrophic pachymeningitis (IHP).

Hypertrophic pachymeningitis is a rare clinical entity characterized by localized or diffuse thickening of the dura mater, with or without associated inflammation. It causes progressive neurological deficit due to compression of the adjacent structures (1).

Headache is the most common initial symptom, followed by ophthalmological symptoms such as vision loss and diplopia (2).

Its etiology is multifactorial. Dural thickening in the posterior cranial fossa, mimicking the Eiffel Tower illuminated at night (Eiffel-by-night sign), is found on imaging studies.

### References

1. Uchida H, Ogawa Y, Tominaga T. Marked effectiveness of low-dose oral methotrexate for steroid-resistant idiopathic hypertrophic pachymeningitis: Case report. *Clin Neurol Neurosurg*. 2018 May;168:30–3.
2. Hahn LD, Fulbright R, Baehring JM. Hypertrophic pachymeningitis. *J Neurol Sci*. 2016 Aug;367:278–83.
3. Dash GK, Thomas B, Nair M, Radhakrishnan A. Clinico-radiological spectrum and outcome in idiopathic hypertrophic pachymeningitis. *J Neurol Sci*. 2015 Mar;350(1–2):51–60.

Dres. Mauricio Andrés Uribe-Valencia y Janeth Jurado Delgado: Médicos Residentes de Geriátría, Universidad del Valle, Hospital Universitario del Valle. Cali (Colombia). Correspondencia: Dr. Mauricio Andrés Uribe-Valencia. Cali (Colombia).

E-mail: [mauricio.uribe@correounivalle.edu.co](mailto:mauricio.uribe@correounivalle.edu.co)  
Received: 11/V/2020 Accepted: 12/VIII/2020

